

Proposed Diagnostic Criteria for the Brugada Syndrome Consensus Report

Arthur A.M. Wilde, MD, PhD; Charles Antzelevitch, PhD; Martin Borggrefe, MD, PhD;
Josep Brugada, MD; Ramón Brugada, MD; Pedro Brugada, MD, PhD; Domenico Corrado, MD;
Richard N.W. Hauer, MD, PhD; Robert S. Kass, PhD; Koonlawee Nademanee, MD;
Silvia G. Priori, MD, PhD; Jeffrey A. Towbin, MD; for the Study Group on the Molecular Basis of
Arrhythmias of the European Society of Cardiology

A syndrome characterized by ST-segment elevation in right precordial leads (V_1 to V_3) that is unrelated to ischemia, electrolyte disturbances, or obvious structural heart disease was reported as early as 1953,¹ but was first described as a distinct clinical entity associated with a high risk of sudden cardiac death in 1992.²⁻⁴ The Brugada syndrome is a familial disease that displays an autosomal dominant mode of transmission, with incomplete penetrance and an incidence ranging between 5 and 66 per 10 000. In regions of Southeast Asia where it is endemic, the clinical presentation of Brugada syndrome is distinguished by a male predominance (8:1 ratio of male:female) and the appearance of arrhythmic events at an average age of 40 years (range: 1 to 77 years).^{2,5} Although a number of candidate genes are considered plausible, thus far the syndrome has been linked only to mutations in *SCN5A*, the gene encoding for the α subunit of the sodium channel.⁶

A number of ambiguities exist concerning the diagnosis of Brugada syndrome. The electrocardiographic signature of the syndrome is dynamic and often concealed, but can be unmasked by potent sodium channel blockers such as flecainide, ajmaline, and procainamide,⁷ although the specificity of this effect for uncovering patients at risk for sudden death has been an issue of concern. A recent report by Remme et al⁸ has shown that the number of idiopathic ventricular fibrillation patients diagnosed as having Brugada syndrome is a sensitive function of the diagnostic criteria applied. What are the proper diagnostic criteria for identifying Brugada syndrome? A definitive answer to this question has been out of reach and is the reason for the establishment of a special Arrhythmia Working Group of the European Society of Cardiology that met from August 31 to September 1, 2000. This report is the

consensus statement from that meeting. The diagnostic criteria described herein are based on the currently available clinical data and state-of-the-art understanding of the molecular and cellular mechanisms underlying Brugada syndrome. The proposed criteria must be considered a work in progress that will be fine-tuned as confirmatory data from future molecular studies and prospective trials become available.

Electrocardiographic Characteristics

ECG abnormalities constitute the hallmark of Brugada syndrome. They include repolarization and depolarization abnormalities in the absence of identifiable structural cardiac abnormalities or other conditions or agents known to lead to ST-segment elevation in the right precordial leads (Table 1). Three types of repolarization patterns are recognized (Figure 1). Type 1, described in a 1992 article,² is characterized by a prominent coved ST-segment elevation displaying J wave amplitude or ST-segment elevation ≥ 2 mm or 0.2 mV at its peak followed by a negative T-wave, with little or no isoelectric separation. Type 2 also has a high take-off ST-segment elevation, but in this case, J wave amplitude (≥ 2 mm) gives rise to a gradually descending ST-segment elevation (remaining ≥ 1 mm above the baseline), followed by a positive or biphasic T-wave that results in a saddle back configuration. Type 3 is a right precordial ST-segment elevation of <1 mm of saddle back type, coved type, or both. It should be stressed that delineation of the J wave is sometimes tricky (second ECG in Figure 1) and that these descriptions are based on the correct placement of the precordial leads, although characteristic ECG features obtained with alternative placement of the right precordial leads

From the Experimental and Molecular Cardiology Group, Academic Medical Center, Amsterdam, and the Interuniversity Cardiology Institute, The Netherlands (A.A.M.W.); Masonic Medical Research Laboratory, Utica, NY, (C.A.); Fakultät Klinische Medizin Mannheim, Universität Heidelberg, Mannheim, Germany (M.B.); Cardiovascular Institute, Hospital Clínic, University of Barcelona, Barcelona, Spain (J.B.); Baylor College of Medicine, Houston, Tex (R.B.); Cardiovascular Center, Onze Lieve Vrouwe Ziekenhuis, Aalst, Belgium (P.B.); Divisione di Cardiologia, Università di Padova, Padova, Italy (D.C.); Heart-Lung Center Utrecht, University Medical Center, Utrecht, The Netherlands (R.N.W.H.); Department of Pharmacology, Columbia University, New York, NY (R.S.K.); Division of Cardiology, University of Southern California, Los Angeles (K.N.); Molecular Cardiology and Electrophysiology Laboratories, Fondazione Salvatore Maugeri, Pavia, Italy (S.G.P.); and Department of Pediatrics, Baylor College of Medicine, Houston, Tex (J.A.T.).

Guest editor for this article is Heinn J.J. Wellens, MD, Cardiovascular Research Institute, Maastricht, the Netherlands.

This article is being simultaneously published by the *European Heart Journal*.

Correspondence to Arthur A.M. Wilde, MD, PhD, Laboratory of Experimental Cardiology, M-0-052, Academic Medical Center, P.O. Box 22700, 1100 DE Amsterdam, The Netherlands. E-mail a.a.wilde@amc.uva.nl

(*Circulation*. 2002;106:2514-2519.)

© 2002 American Heart Association, Inc.

Circulation is available at <http://www.circulationaha.org>

DOI: 10.1161/01.CIR.0000034169.45752.4A

TABLE 1. ST-Segment Abnormalities in Leads V₁ to V₃

	Type 1	Type 2	Type 3
J wave amplitude	≥2 mm	≥2 mm	≥2 mm
T wave	negative	positive or biphasic	positive
ST-T configuration	coved type	saddleback	saddleback
ST segment (terminal portion)	gradually descending	elevated ≥1 mm	elevated <1 mm

1 mm=0.1 mV. The terminal portion of the ST segment refers to the latter half of the ST segment.

in a superior intercostal space in individuals with high clinical suspicion (aborted sudden cardiac death victims, family members of patients with Brugada syndrome) may also disclose the presence of the arrhythmic substrate.⁹ In select cases one may even consider rightward displacement. However, the r' deflection in leads V₃R, V₄R, etc, should be interpreted with caution. Characteristic ECG morphologies recorded in the first few hours after resuscitation or immediately after DC shock cannot be taken as diagnostic of the Brugada syndrome. As shown in Figure 1, the ST segment is dynamic. Different patterns may be observed sequentially in the same patient or following the introduction of specific drugs (see below).

The QT-interval is often within normal limits (in the absence of anti-arrhythmic drug therapy), but it may be prolonged. In the initial series described by Brugada and Brugada,² 3 out of 6 males had a QT_c ≥440 ms. In male Thai patients with RBBB and ST-elevation, mean QT_c was slightly longer than normal.¹⁰ Families with (drug-induced) ST-segment elevation and QT prolongation have also been described.^{11,12}

Conduction disorders vary from non-specific to specific for any given part of the conduction system (in drug-free state). To the former category belongs the often-encountered pronounced broad S in leads I, II, and III, giving rise to left or

extreme axis deviation. A left axis may also indicate a left anterior hemiblock. A true RBBB may be seen with or without right or left axis deviation. The high take-off ST segment previously discussed may mimic a RBBB pattern, but the absence of S waves in the left-lateral leads precludes the true presence of right ventricular conduction delay.

The PR interval is often increased (≥200 ms) and presumably reflects the presence of HV-conduction delay (≥55 ms). In a recent survey,⁴ the latter was found to be present in 20/21 Brugada patients, and although it was usually in the range of 65 ms, it may be as long as 110 ms. Eckardt et al, however,¹³ reported a mean HV interval of 49±12 ms in 35 patients, with only 6 patients having an interval over 60 ms.

Particular problems exist in the pediatric population because of the lack of control data, the different chest morphology, and the age-dependent predominance of right ventricular forces. Typical ECG patterns, however, have been observed in small infants, where eventual lethal arrhythmias might actually resemble Sudden Infant Death Syndrome.^{5,14} Hence, suspect symptoms with typical electrocardiographic features and/or a family history for sudden cardiac death, even at young age, should alert pediatricians to the possibility of Brugada syndrome.

Drug Challenge

Intravenous administration of certain drugs may modify the ECG pattern. Ajmaline (1 mg/kg body weight; 10 mg/min), flecainide (2 mg/kg, max. 150 mg; in 10 minutes), and procainamide (10 mg/kg; 100 mg/min) exaggerate the ST-segment elevation or unmask it when it is initially absent. Sensitivity and specificity (with genetic data as the gold standard) for intravenous drug challenges are disputed.^{7,12} There is consensus, however, that in the case of procainamide, sensitivity is relatively low. Reproducibility of the test has not been established, and a recent study suggests that it might be less than 100%.¹⁵

Drug challenge should be performed while the patient is continuously monitored (12 lead ECG and blood pressure) and with defibrillator and advanced coronary life support facilities close at hand. Accurate lead position and correct venous access should be ascertained. Drug administration should be stopped when the test is positive (see below) and/or when ventricular arrhythmias, including ventricular premature complexes, are evident, or when significant QRS widening (≥30%) is observed. In the case of a negative baseline ECG, a J-wave amplitude of >2 mm absolute amplitude in lead V₁ and/or V₂ and/or V₃ with or without RBBB is considered positive. In patients with type 1 ECGs, drug testing is not of additional diagnostic value. In patients with

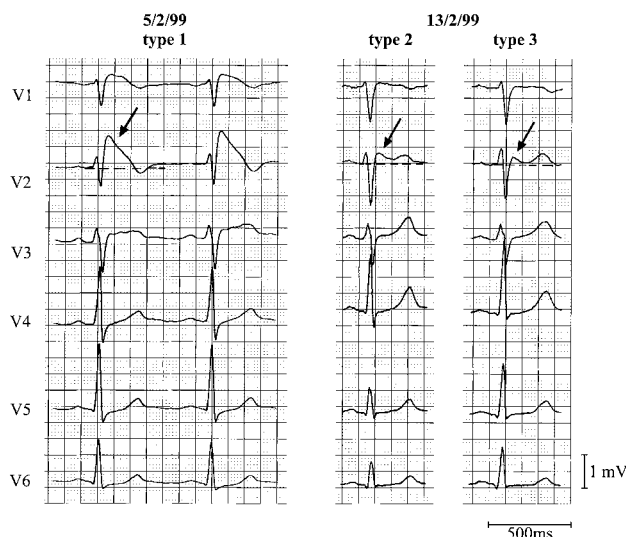


Figure 1. Precordial leads of a resuscitated patient with Brugada syndrome. Note the dynamic ECG changes in the course of a couple of days. All 3 patterns are shown. Arrows denote the J-wave (see text for definition). The left panel shows a clear type 1 ECG. Between 7-2-99 and 13-2-99, types 2 and 3 are shown. Calibrations are given.

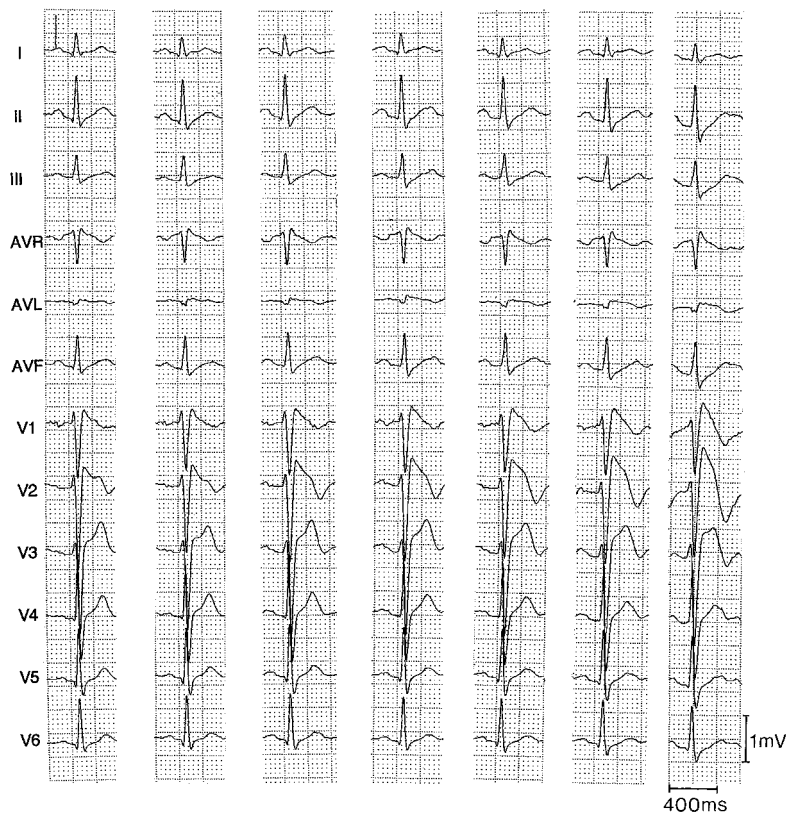


Figure 2. ECGs from a 35-year-old male who has been successfully resuscitated. From left to right: 2 control ECGs and 1, 2, 3, 4, and 5 minutes during IV infusion of 50 mg ajmaline. The ECG is “saddle back” type (type 2) in the left panels and becomes covered in the right panels (type 1). Calibrations are standard.

type 2 and type 3 ECGs, the test is recommended to clarify the diagnosis. Conversion of a type 2 or 3 ECG to a type 1 is considered positive (Figure 2). An increase in the J-wave amplitude of more than 2 mm without the development of a type 1 configuration is also considered significant, but in our experience is rarely observed. Conversion of type 3 ECG into type 2 is considered inconclusive.

Monitoring is recommended until the ECG has normalized (plasma half-life of flecainide is 20 hours, of procainamide is 3 to 4 hours, and ajmaline inactivated within a few minutes). Serious ventricular arrhythmias, including ventricular fibrillation (VF), may occur during the test. Immediate discontinuation of the drug is required, and isoproterenol infusion might be needed to treat the arrhythmias (1 to 3 $\mu\text{g}/\text{min}$ isoproterenol¹⁴; P. Brugada, personal observations, 1999).

It seems intuitive that the more sodium channel block is needed to elicit the Brugada phenotype, the less likely the patient is to be at risk under baseline conditions. Indeed, it was recently shown that asymptomatic patients with an abnormal ECG only on drug challenge have a benign prognosis.¹⁶ Canine ventricular wedge studies suggest that a flecainide-induced Brugada phenotype does not necessarily indicate the presence of an arrhythmic substrate; it does denote the ability of sodium channel block to create the conditions under which the arrhythmic substrate may readily develop.¹⁷

Clinical Presentation

All too often, syncope or sudden cardiac death is the only symptom in patients with Brugada syndrome. In some cases, sudden death is the first symptom of the disease. Monitoring

of such patients has revealed rapid polymorphic ventricular tachycardias (VTs) as the underlying cause. VT usually starts with a short coupling interval. Self-terminating episodes typically lead to repeated episodes of syncope. Indeed, 80% of patients with documented VF have a history of syncope.¹⁵ Clinical reports indicate that sudden death in patients with Brugada syndrome most commonly occurs during sleep, in particular during the early morning hours.^{9,18}

It has been suggested that there is a higher-than-normal incidence of supraventricular tachyarrhythmias, including atrial and atrioventricular reentrant tachycardia in the Brugada population.¹³ Rarely, monomorphic VT is observed.^{19,20} Family history is of paramount importance and is often positive for sudden cardiac death at a young age.

The mean age at which symptoms first appear in affected individuals (males and females) is in the third to fourth decade. Among the first patients described, however, were symptomatic twins who were 1 year of age, and more recent reports describe families with symptomatic children.^{5,14} A patient in which first symptoms appeared at an age of 77 years has also been described.²

Electrophysiological Studies

Electrophysiological studies (EPSs) may be helpful in risk stratification and in some cases in establishing the diagnosis. A complete EPS is recommended in all symptomatic patients. In VF survivors, EPS may be of little or no diagnostic value, but may be helpful in providing further insight into the predictive value of available diagnostic tools. In the absence of data on sensitivity or specificity of any EPS protocol, we suggest a protocol using 2 stimulation sites (right ventricular

TABLE 2. Abnormalities That Can Lead to ST-Segment Elevation in the Right Precordial Leads

Right or left bundle branch block, left ventricular hypertrophy ²⁸
Acute myocardial ischemia or infarction ²⁹
Acute myocarditis ³⁰
Right ventricular ischemia or infarction ³¹
Dissecting aortic aneurysm ³²
Acute pulmonary thromboemboli ³³
Various central and autonomic nervous system abnormalities ^{34,35}
Heterocyclic antidepressant overdose ³⁶
Duchenne muscular dystrophy ³⁷
Friedreich's ataxia ³⁸
Thiamine deficiency ^{39,40}
Hypercalcemia ⁴¹
Hyperkalemia ⁴²
Cocaine intoxication ^{43,44}
Mediastinal tumor compressing RVOT ⁴⁵
Arrhythmogenic right ventricular dysplasia/cardiomyopathy ^{24,25}
Long-QT syndrome, type 3 ^{11,12}
Other conditions that can lead to ST-segment elevation in the right precordial leads
Early repolarization syndrome
Other normal variants (particularly in men) ²⁶

Whereas the last 2 "other conditions that can lead to ST-segment elevation" are more likely to give rise to type 2 and type 3 ECGs, most conditions mentioned in this table can give rise to type 1 ECG.

apex [RVA] and right ventricular outflow tract), at least 3 cycle lengths (600, 430, and 330 ms), 1, 2, and 3 extrastimuli, and a minimal coupling interval of 200 ms. At present, it is unknown whether shortening of the coupling interval to refractoriness, which might be very short in patients with Brugada syndrome, has additive value. Inducibility early in the protocol is common, but non-inducible cases have been described. About half of patients are inducible from the outflow tract. Isoproterenol does not enhance the likelihood of inducibility and in theory should have the opposite effect. The diagnostic value of repeating an EPS after class I drug treatment (or challenge) is not fully established. Similarly, the value of epicardial stimulation,²¹ as well as the value of right ventricular mapping with monophasic action potentials, is not known.²² Asymptomatic patients with a positive family history for SCD should be investigated in a similar way. The necessity for EPS is questionable in patients who display the Brugada ECG but who are asymptomatic and have a negative family history. In fact, accuracy to predict outcome is debated. Positive predictive value varies from 50%¹⁵ to 37%,²³ and negative predictive value varies from 46%¹⁵ to 97%.^{16,23}

Differential Diagnosis

The list of factors contributing to ST-segment elevation is long (Table 2). Clinical diagnostic evaluation should be directed toward excluding each of these causes. Discrimination between Brugada syndrome and arrhythmogenic right ventricular cardiomyopathy (ARVC) may be particularly

difficult because ARVC may at times mimic Brugada syndrome and structural abnormalities may only be found at time of autopsy.^{24,25} Before the diagnosis Brugada syndrome is made, a serious attempt should be taken to exclude ARVC. Drug challenge with sodium channel blockers may be useful in discriminating between these 2 diseases.⁷ Intuitively, one would expect a rightward shift of the ϵ wave, if present, in ARVC patients. Table 3 lists characteristics of the 2 diseases that may be useful in making a differential diagnosis.

Brugada syndrome should also be distinguished from early repolarization syndrome (with an eventual elevated J-wave amplitude in the left precordial leads) and from normal degrees of right precordial ST elevation in men, which may mimic a type 2 or 3 Brugada ECG pattern.²⁶ Once again, a drug challenge might provide the clue for a proper diagnosis.

Molecular Genetics

Genetic linkage analysis may be of great help in arriving at a definitive diagnosis. There are several limitations, however. First, it may take weeks to months before a mutation in *SCN5A*, the only gene thus far causally linked to Brugada syndrome, is identified. Second, there are few diagnostic laboratories capable of screening for the disease. Third, only a small fraction of patients can be successfully genotyped at this time (estimates vary between 10% and 30%). With the identification of other genes, this fraction will increase in future years. Finally, the identification of a new mutation in a sporadic case is equivocal at best. In such cases, data concerning the function of the abnormally encoded protein may be helpful in substantiating the physiological relevance of the gene mutation and in estimating the level of clinical risk. With regard to screening of relatives, a "proven" mutation in the proband could enable better follow-up and possibly more effective treatment of family members who may still be asymptomatic.

SCN5A mutations linked to Brugada syndrome have been found throughout the gene.²⁷ A common denominator in all of these is a functional reduction in the availability of sodium channel current. Mechanisms identified thus far include failure of the channel to express, accelerated or premature inactivation, shifts of the steady state inactivation curves to more negative values, and increased likelihood for the channel to enter an intermediate inactivated state (with slow recovery kinetics).²⁷

The Diagnosis of Brugada Syndrome

Brugada syndrome should be strongly considered in the following cases:

1) Appearance of a type one ST-segment elevation (coved type, Table 1) in more than one right precordial lead (V_1 to V_3), in the presence or absence of a sodium channel blocker, and one of the following likely indicates Brugada syndrome: documented ventricular fibrillation; self terminating polymorphic ventricular tachycardia; a family history of SCD (<45 years); coved type ECGs in family members; electrophysiological inducibility; syncope; or nocturnal agonal respiration. There should be no other factor(s) that can account for the ECG abnormality. The appearance of the ECG features without these clinical

TABLE 3. Differential Diagnosis Between ARVC and Brugada Syndrome

Clinical Characteristics	ARVC	Brugada Syndrome
Age at presentation, y	25–35	35–40
Sex, male:female	3:1	8:1
Distribution	Worldwide*	Worldwide*
Inheritance	AD(AR)	AD
Chromosomes	1,2,3,10,14 (17)	3
Gene	<i>hRYR2</i> , <i>plakoglobin</i>	<i>SCN5A</i>
Symptoms	Palpitations Syncope Cardiac arrest	Syncope Cardiac arrest
Circumstances	Effort	Rest
Imaging	Morphofunctional RV (and LV) abnormalities	Normal
Pathology	Fibrofatty replacement	Normal
ECG repolarization	Inverted T waves in precordial leads	High take-off ST segment V ₁ to V ₃
ECG depolarization	ϵ -waves QRS prolongation	RBBB/LAD
AV conduction	Normal	50% abnormal PR/HV
Atrial arrhythmias	Late (secondary)	Early (primary 10% to 25%)
ECG changes	Fixed (mostly)	Variable
Ventricular arrhythmias	Monomorphic VT/VF	Polymorphic VT/VF
Mechanism of arrhythmias	Scar-related	Phase 2
Drug effect class I	↓	↑
Drug effect class II	↓	↑
Drug effect class III	↓	–/↑
Drug effect class IV	–/↓	–
β -stimulation	↑	↓
Natural history	Sudden death Heart failure	Sudden death

Arrows indicate changes in ST segment elevation; ↑, increased; ↓, decreased; and –/, small change, if any.

*ARVC is frequently found in Northeast Italy, and Brugada syndrome may be particularly prevalent in South-East Asia.

symptoms is referred to as an idiopathic Brugada ECG pattern (not Brugada syndrome).

2) Appearance of type 2 ST-segment elevation (“saddle-back type”) in more than 1 right precordial lead under baseline conditions with conversion to type 1 after challenge with a sodium channel blocker is considered equivalent to case 1 above. A drug-induced ST-segment elevation to a value >2 mm should raise the possibility of Brugada syndrome when 1 or more clinical criteria are present (see case 1 above). On the basis of our limited knowledge at present, a patient with a negative drug test (ie, no change in the ST-segment in response to a sodium channel blocker) is unlikely to have the Brugada syndrome; drug-induced ST elevation to <2 mm is considered inconclusive.

3) Appearance of type 3 ST segment elevation in more than 1 lead under baseline conditions with conversion to type 1 after challenge with a sodium channel blocker is considered equivalent to case 1 above and should be screened accordingly. Drug-induced conversion of type 3 to type 2 ST-segment elevation is considered inconclusive.

Patients who do not fully fulfill the proposed criteria (eg, type 1 ECG with a J-wave amplitude of only 1 mm),

but who have one or more of the clinical criteria defined above, should be considered seriously. Most often, a drug challenge will disclose the diagnosis Brugada syndrome. In addition, in these and other cases mentioned, EPS might be useful.

Limitations

This consensus meeting started to develop a diagnostic scheme similar to “point systems” available for other arrhythmogenic disorders like the long QT syndrome. It was abandoned, however, when we came to the realization that such a quantitative approach would require more data than currently available. In particular, we lack data on the spectra of ECG patterns that may be associated with an increased risk of death. Because of that fact, we would like to stress once again that the proposed criteria are based on currently available data and that it is a work in-progress that is awaiting confirmatory molecular, patho-anatomical, and prospective clinical data. In particular, discrimination from ARVC should receive due attention.

Acknowledgments

We gratefully acknowledge educational grants from the Working Group on Arrhythmias of the European Society of Cardiology, Guidant, Medtronic, and the Ramon Brugada Senior Foundation.

References

- Osher HL, Wolff L. Electrocardiographic pattern simulating acute myocardial injury. *Am J Med Sci.* 1953;226:541–545.
- Brugada P, Brugada J. Right bundle branch block, persistent ST segment elevation and sudden cardiac death: a distinct clinical and electrocardiographic syndrome: a multicenter report. *J Am Coll Cardiol.* 1992;20:1391–1396.
- Antzelevitch C, Brugada P, Brugada J, et al. *The Brugada Syndrome*. Armonk, NY: Futura Publishing Company, Inc; 1999:1–99.
- Alings M, Wilde A. “Brugada” syndrome: clinical data and suggested pathophysiological mechanism. *Circulation.* 1999;99:666–673.
- Priori SG, Napolitano C, Giordano U, et al. Brugada syndrome and sudden cardiac death in children. *Lancet.* 2000;355:808–809.
- Chen Q, Kirsch GE, Zhang D, et al. Genetic basis and molecular mechanisms for idiopathic ventricular fibrillation. *Nature.* 1998;392:293–296.
- Brugada R, Brugada J, Antzelevitch C, et al. Sodium channel blockers identify risk for sudden death in patients with ST-segment elevation and right bundle branch block but structurally normal hearts. *Circulation.* 2000;101:510–515.
- Remme CA, Wever EFD, Wilde AAM, et al. Diagnosis and long-term follow-up of Brugada syndrome in patients with idiopathic ventricular fibrillation. *Eur Heart J.* 2001;22:400–409.
- Shimizu W, Matsuo K, Takagi M, et al. Body surface distribution and response to drugs of ST segment elevation in Brugada syndrome: clinical implications of eighty-seven-lead body surface potential mapping and its application to twelve-lead electrocardiograms. *J Cardiovasc Electrophysiol.* 2000;11:396–404.
- Nademanee K, Veerakul G, Nimmannit S, et al. Arrhythmogenic marker for the sudden unexplained death syndrome in Thai men. *Circulation.* 1997;96:2595–2600.
- Bezzina C, Veldkamp MW, Van den Berg MP, et al. A single Na⁺ channel mutation causing both long-QT and Brugada syndromes. *Circ Res.* 1999;85:1206–1213.
- Priori SG, Napolitano C, Schwartz PJ, et al. The elusive link between LQTS and Brugada syndrome: the role of flecainide challenge. *Circulation.* 2000;102:945–947.
- Eckardt L, Kirchhof P, Loh P, et al. Brugada syndrome and supraventricular tachyarrhythmias: a novel association? *J Cardiovasc Electrophysiol.* 2001;12:680–685.
- Suzuki H, Torigoe K, Numata O, et al. Infant case with a malignant form of Brugada syndrome. *J Cardiovasc Electrophysiol.* 2000;11:1277–1280.
- Priori SG, Napolitano C, Gasparini M, et al. Clinical and genetic heterogeneity of right bundle branch block and ST-segment elevation syndrome: a prospective evaluation of 52 families. *Circulation.* 2000;102:2509–2515.
- Brugada J, Brugada R, Antzelevitch C, et al. Long-term follow-up of individuals with the electrocardiographic pattern of right bundle-branch block and ST-segment elevation in precordial leads V₁ to V₃. *Circulation.* 2002;105:73–78.
- Antzelevitch C. The Brugada syndrome: ionic basis and arrhythmia mechanisms. *J Cardiovasc Electrophysiol.* 2001;12:268–272.
- Matsuo K, Kurita T, Inagaki M, et al. The circadian pattern of the development of ventricular fibrillation in patients with Brugada syndrome. *Eur Heart J.* 1999;20:465–470.
- Shimada M, Miyazaki T, Miyoshi S, et al. Sustained monomorphic ventricular tachycardia in a patient with Brugada syndrome. *Jpn Circ J.* 1996;60:364–370.
- Boersma LVA, Jaarsma W, Jessurun ER, et al. Brugada syndrome: a case report of monomorphic ventricular tachycardia. *Pacing Clin Electrophysiol.* 2001;24:112–115.
- Carlsson L, Erdogan ASB, Neuzner J, et al. Possible role of epicardial left ventricular programmed stimulation in Brugada syndrome. *Pacing Clin Electrophysiol.* 2001;24:247–249.
- Eckardt L, Kirchhof P, Johna R, et al. Transient local changes in right ventricular monophasic action potentials due to ajmaline in a patient with Brugada syndrome. *J Cardiovasc Electrophysiol.* 1999;10:1010–1015.
- Brugada P, Geelen P, Brugada R, et al. Prognostic value of electrophysiological investigations in Brugada syndrome. *J Cardiovasc Electrophysiol.* 2001;12:1004–1007.
- Corrado D, Nava A, Buja G, et al. Familial cardiomyopathy underlies syndrome of right bundle branch block, ST-segment elevation and sudden death. *J Am Coll Cardiol.* 1996;27:443–448.
- Corrado D, Basso C, Buja G, et al. Right bundle branch block, right precordial ST-segment elevation and sudden death in young people. *Circulation.* 2001;103:710–717.
- Macfarlane PW, Lawrie TDV, eds. The normal electrocardiogram and vectorcardiogram. In: *Comprehensive Electrocardiology: Theory and Practice in Health and Disease*. Vol 1. New York, NY: Pergamon Press, 1989:407–457.
- Bezzina CR, Rook MB, Wilde AAM. Cardiac sodium channel and inherited arrhythmia syndromes. *Cardiovasc Res.* 2001;49:257–271.
- Rowlands DJ. *Clinical Electrocardiography*. Philadelphia, Pa: JB Lippincott Company; 1991.
- Goldberger AL. *Myocardial Infarction: Electrocardiographic Differential Diagnosis*. 4th ed. St. Louis, Mo: Mosby Year Book Inc, 1991.
- Spodick DH, Greene TO, Saperia G. Acute myocarditis masquerading as acute myocardial infarction. *Circulation.* 1995;91:1886–1887.
- Andersen HR, Falk E, Nielsen D. Right ventricular infarction: the evolution of ST-segment elevation and Q wave in right chest leads. *J Electrocardiol.* 1989;22:181–186.
- Myers GB. Other QRS-T pattern that may be mistaken for myocardial infarction. IV: alterations in blood potassium: myocardial ischemia; sub-epicardial myocarditis; distortion associated with arrhythmias. *Circulation.* 1950;2:75–93.
- Sreeram N, Cheriex EC, Smeets JL, et al. Value of the 12-lead electrocardiogram at hospital admission in the diagnosis of pulmonary embolism. *Am J Cardiol.* 1994;73:298–303.
- Abbott JA, Cheitlin MD. The nonspecific camel-hump sign. *JAMA.* 1976;235:413–414.
- Hersch C. Electrocardiographic changes in head injuries. *Circulation.* 1961;23:853–860.
- Bolognesi R, Tsialtas D, Vasini P, et al. Abnormal ventricular repolarization mimicking myocardial infarction after heterocyclic antidepressant overdose. *Am J Cardiol.* 1997;79:242–245.
- Perloff JK, Henze E, Schelbert HR. Alterations in regional myocardial metabolism, perfusion, and wall motion in Duchenne muscular dystrophy studied by radionuclide imaging. *Circulation.* 1984;69:33–42.
- Grauer K. Bizarre ECG in a young adult. *Intern Med Alert.* 1997;19:56.
- Read DH, Harrington DD. Experimentally induced thiamine deficiency in beagle dogs: clinical observations. *Am J Vet Res.* 1981;42:984–991.
- Hundley JM, Ashburn LL, Sebrell WH. The electrocardiogram in chronic thiamine deficiency in rats. *Am J Physiol.* 1954;144:404–414.
- Douglas PS, Carmichael KA, Palvsky PM. Extreme hypercalcemia and electrocardiographic changes. *Am J Cardiol.* 1984;54:674–675.
- Levine HD, Wanzer SH, Merrill JP. Dialyzable currents of injury in potassium intoxication resembling acute myocardial infarction or pericarditis. *Circulation.* 1956;13:29–36.
- Lipski J, Stimmel B, Donoso E. The effect of heroin and multiple drugs abuse on the electrocardiogram. *Am Heart J.* 1973;86:663–668.
- Littmann L, Monroe MH, Svenson RH. Brugada-type electrocardiographic pattern induced by cocaine. *Mayo Clin Proc.* 2000;75:845–849.
- Tarin N, Farré J, Rubio JM, et al. Brugada-like electrocardiographic pattern in a patient with a mediastinal tumor. *Pacing Clin Electrophysiol.* 1999;22:1264–1266.

KEY WORDS: death, sudden ■ arrhythmia ■ genetics